

May 2021

Case Study on InHome Patient W94 Receiving Home Health Care

Wound Type: Diabetic Wound

Location: Plantar Surface of Right Foot

Date Acquired: April 28, 2021

Patient's Age: 62 Years Old

Past History & Physical:

62-year-old presented to the hospital with a right foot diabetic ulcer. Patient has history of uncontrolled diabetes mellitus (DM), obesity and peripheral arterial disease (PAD).

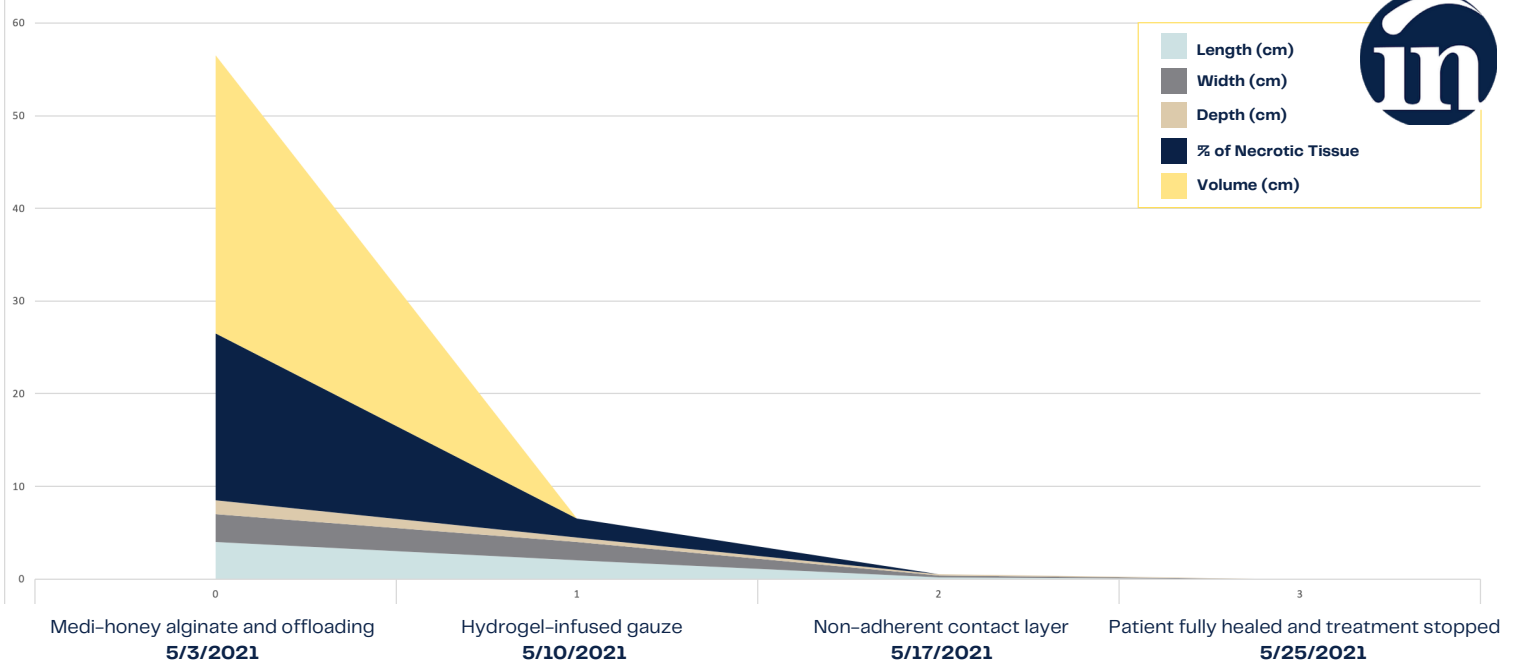
Initial Findings:

Patient was admitted to the hospital with diabetic wound to the right foot with unstable eschar covering 100% on wound. Surgical debridement occurred on 04/29/21. Patient was discharged to home with home health care from InHome Health Care Services.

Course of Treatment:

Patient was admitted to InHome Healthcare Services. Patient was instructed on proper offloading techniques secondary to wound being on the plantar surface of the foot. Patient was initially treated with Medi-Honey alginate with progression and switched to a hydrogel-infused gauze and eventually to a non-adherent contact layer until the wound healed. **The wound healed with 30 days of onset.**

InHome Patient Wound Volume By Week



Date	Modality of Treatment	Weeks in Treatment	Length (cm)	Width (cm)	Depth (cm)	Volume (cm)	% of Necrotic Tissue	% of Granulation Tissue
5/3/2021	Medi-honey alginate and offloading	0	4	3	1.5	18.00000	30	70
5/10/2021	Hydrogel-infused gauze	1	2	2	0.5	2.00000	0	100
5/17/2021	Non-adherent contact layer	2	0.2	0.2	0.1	0.00040	0	100
5/25/2021	Patient fully healed and treatment stopped	3	0	0	0	0.00000	0	100

Analysis performed by Matthew Cranfill, RN

For more information on our wound care program, please contact matt.cranfill@inhomehcs.com